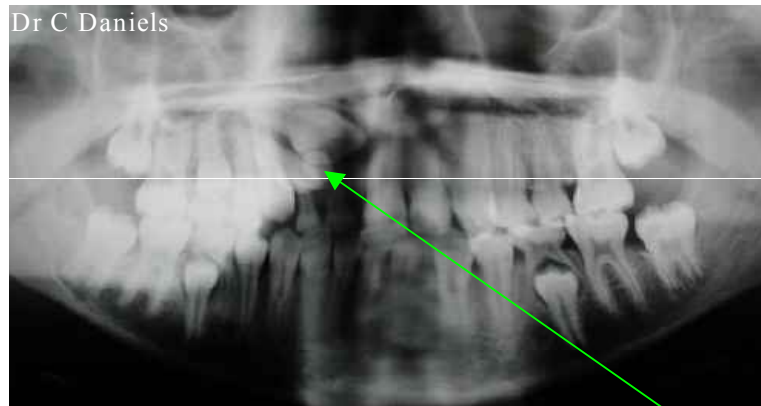
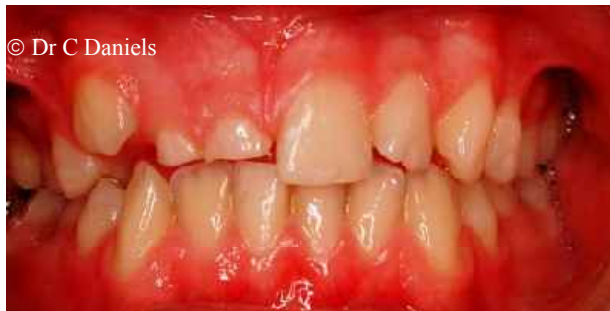

Orthodontic treatment cases

Age young child. **Problem** An extra tooth is present that is blocking the eruption of the upper right central and lateral incisors.

Treatment : The supernumerary tooth and deciduous teeth were removed and attachments placed on the buried incisors. Treatment completed in 24 months



Extra tooth

